



## PATIENT

Chewie Hanson

## SPECIES

Canine

## BREED

Dachshund

## SEX

FS

## AGE

14yr

## WEIGHT

15.6

## PRESENTING CLINICAL SIGNS

- Elevated liver enzymes, recheck previous stage B1 DMVD.
- On Movoflex
- Abnormal PE/Chem/CBC/UA Results: ALT 138 U/L, ALP 1,023 U/L, GGT 23 U/L

## ULTRASONOGRAPHIC EXAMINATION OF THE ABDOMEN AND HEART

CANINE CARDIAC PARAMETERS	MR VMAX (m/s)	TR VMAX (m/s)	LA/AO M-mode	LA/AO (Heart Base; Swe)	FS (%)	EF (%)	EPSS (cm)
NORMAL PARAMETER	4.5-5.5	<2.7	1.3	Up to 1.6	28-40	40-100	<0.6
PATIENT	--	--	--	1.46	50	82	0.1
CANINE CARDIAC PARAMETERS	HR (BPM)	AV VMAX (m/s)	PV MAX (m/s)	BODY WEIGHT	LAD LA MAX 4 Chamber	LVIDd Avg; 2D and m-mode short axis (cm)	LVIDs Avg; 2D and m-mode short axis (cm)
NORMAL PARAMETER	50-100	0.7-1.7	0.7-1.6				
PATIENT	NM	1.0	0.6	15.6	2.7	2.5	--

## INTERPRETED BY

R. McKenzie Daniel,  
DVM, DABVP  
(Canine and Feline)

## IMAGING PERFORMED BY

Christensen

## HOSPITAL NAME

Tranquility Veterinary  
Clinic

## REFERRING VET

House

## INVOICE 23930

DATE  
02/18/2026

### Cardiac Presentation

The echocardiogram in this patient demonstrated normal left atrial size based on 2 different LA measurement methods. Chamber volumes and echogenicity were normal. The cranial and caudal mitral valve leaflets presented vegetative thickening consistent with endocardiosis. Doppler indicated measurable moderate eccentric insufficiency. The left ventricle presented thicknesses with linear contour and was not dilated nor restricted. The myocardium presented normal echogenicity without subjective evidence of significant fibrotic or ischemic disease. Contractility of the ventricular walls was adequate and in normal range for this patient evidenced by the fractional shortening measurement and subjective evaluation of the different regions of the myocardium. The left ventricular outflow tract demonstrated normal laminar flow and subjective structural integrity. Normal measured LVOT velocity. The right atrium and auricle revealed normal size, structure and content. No evidence of masses was noted or chamber overload. Tricuspid valvular assessment demonstrated adequate linear morphology. The right ventricle was of normal size (1/3 diameter of LV), chordae structure, myocardial echogenicity and thickness. Pulmonic tract assessment revealed normal valve structure, laminar flow, and diameter (approx.1:1 pa/ao ratio). Normal measured RVOT velocity with mild pulmonic insufficiency on Doppler. PV insufficiency 1.2 m/s. No visible pericardial or free pleura fluid was noted. No echographically detectable evidence of infiltrative disease was visible. The cranial mediastinum and pericardial regions were free of masses in the visible window.

### Urinary System

The urinary bladder, trigone, cystourethral junction, and visible pelvic urethra to a depth of 3 cm exhibited normal thickness and tone. Anechoic urine was present in the lumen with mild non-



## PATIENT

Chewie Hanson

## SPECIES

Canine

## BREED

Dachshund

## SEX

FS

## AGE

14yr

## WEIGHT

15.6

## INTERPRETED BY

R. McKenzie Daniel,  
DVM, DABVP  
(Canine and Feline)

## IMAGING PERFORMED BY

Christensen

## HOSPITAL NAME

Tranquility Veterinary  
Clinic

## REFERRING VET

House

## INVOICE

23930

## DATE

02/18/2026

dependent particulate sediment. The ureteral papillae were normal. The ureters were not visible which is normal. No evidence of inflammatory or neoplastic changes was noted.

Normal size and margination were present in the kidneys. A normal 1:3 cortex / medulla ratio was maintained. The medulla and cortices were uniform in texture with some increased echogenicity and moderate loss of corticomedullary symmetry and definition expected for the age of the patient. No evidence of pelvic dilation was present. Areas of medullary mineral and intermittent small cortical cysts. The left kidney measured 4.6 cm in length. The right kidney measured 4.2 cm in length.

The area of the aortic trifurcation was free of pathology.

### **Adrenal Glands**

The bilateral adrenal glands were mildly enlarged in size. Mild parenchyma heterogeneity and mild capsule asymmetry was present without suspicion for overt neoplasia. The left adrenal gland measured 0.64 cm width in the caudal pole. The right adrenal gland measured 0.63 cm width in the caudal pole.

### **Spleen**

The spleen exhibited a finely textured and homogenous parenchyma which was hyperechoic to the liver and renal cortical parenchyma. The capsule was smooth and regular without apparent expansion. The splenic vasculature at the hilus was normal in volume with no evidence of congestion or thrombosis. Acute to chronic inflammatory, neoplastic, or benign parenchyma changes were not noted.

### **Liver/Gallbladder**

The liver was subjectively mildly enlarged. The liver parenchyma was mildly nonuniform and hypoechoic to the spleen with a moderate coarse echotexture and subjective mild to benign parenchymal remodeling. The hepatic and portal vasculature were normal in appearance without signs of congestion. The gallbladder was non-distended in size with thin walls and mild non-organized debris. The cystic and common bile ducts were normal.

### **Gastrointestinal**

The stomach presented intact wall layering with a normal wall layer ratio. The lumen of the stomach was empty with no signs of ileus, obstruction or foreign material.

The small intestine presented intact wall layering with 1:3 muscularis/mucosa ratio. The lumen of the small intestine was empty with no signs of mechanical/metabolic ileus, obstruction or foreign material.

Normal visible colon wall layers were present with apparent formed feces in lumen.

### **Pancreas**

The pancreas was mildly prominent in size with isoechoic to heterogeneous parenchyma compared to adjacent omentum. No signs of active inflammation or neoplasia.

### **Free Abdomen**

No omental masses, overt lymphadenopathy or peritoneal effusion was present.

## ULTRASONOGRAPHIC FINDINGS

### Primary



## PATIENT

Chewie Hanson

## SPECIES

Canine

## BREED

Dachshund

## SEX

FS

## AGE

14yr

## WEIGHT

15.6

## INTERPRETED BY

R. McKenzie Daniel,  
DVM, DABVP  
(Canine and Feline)

## IMAGING PERFORMED BY

Christensen

## HOSPITAL NAME

Tranquility Veterinary  
Clinic

## REFERRING VET

House

## INVOICE

23930

## DATE

02/18/2026

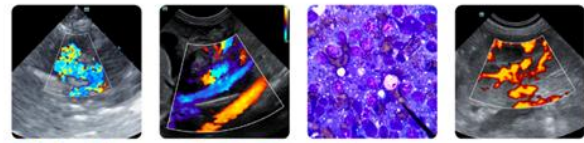
- Persistent chronic mitral valve disease (B1)
- Mild pulmonic valve insufficiency - not hemodynamically significant
- Enlarged non-homogenous liver
- Mild gallbladder debris (non-mucocele)
- Chronic renal changes exhibiting medullary mineral and cortical cysts
- Bilateral mild adrenomegaly
- Mild urine sediment
- Mildly prominent remodeled pancreas

## INTERPRETATION OF THE FINDINGS & FURTHER RECOMMENDATIONS

The liver is most consistent with chronic benign hepatopathy criteria, such as chronic vacuolar hepatopathy, inflammatory disease, hyperplasia, fibrosis or other with hepatic neoplasia considered less likely. Adrenal workup indicated if clinical signs consistent with Cushing's syndrome are present. Hepatosupportive medications may prove beneficial. A spec CPL is warranted if previous or non-reported clinical signs which may suggest chronic pancreatitis are present. The urinary bladder sediment may suggest cellular / crystalline debris or mucus. Cystocentesis for UA +/- C/S if evidence of inflammatory cells is recommended.

The cause of the murmur is subjective mild chronic degenerative valvular changes with secondary MR. No evidence of additional issues such as DCM criteria, LV systolic dysfunction or clinical pulmonary hypertension. The lack of left atrial enlargement implies that the risk of complication secondary to mitral valve insufficiency is relatively low at this time and, without current clinical signs, indicates that medical therapy is not required at this stage. Prognosis at this stage is variable and serial sonographic monitoring is recommended with a recheck echocardiogram in 6 months, sooner if clinical signs suggestive of heart disease develop.

No anesthetic contraindications. Suggested anesthetic protocol may include opioid or Benzodiazepine pre-med, induction with Propofol or Alfaxalone, and appropriate gas anesthesia with avoidance of alpha 2 agonists.



**PATIENT**

Chewie Hanson

**SPECIES**

Canine

**BREED**

Dachshund

**SEX**

FS

**AGE**

14yr

**WEIGHT**

15.6

**INTERPRETED BY**

R. McKenzie Daniel,  
DVM, DABVP  
(Canine and Feline)

**IMAGING PERFORMED BY**

Christensen

**HOSPITAL NAME**

Tranquility Veterinary  
Clinic

**REFERRING VET**

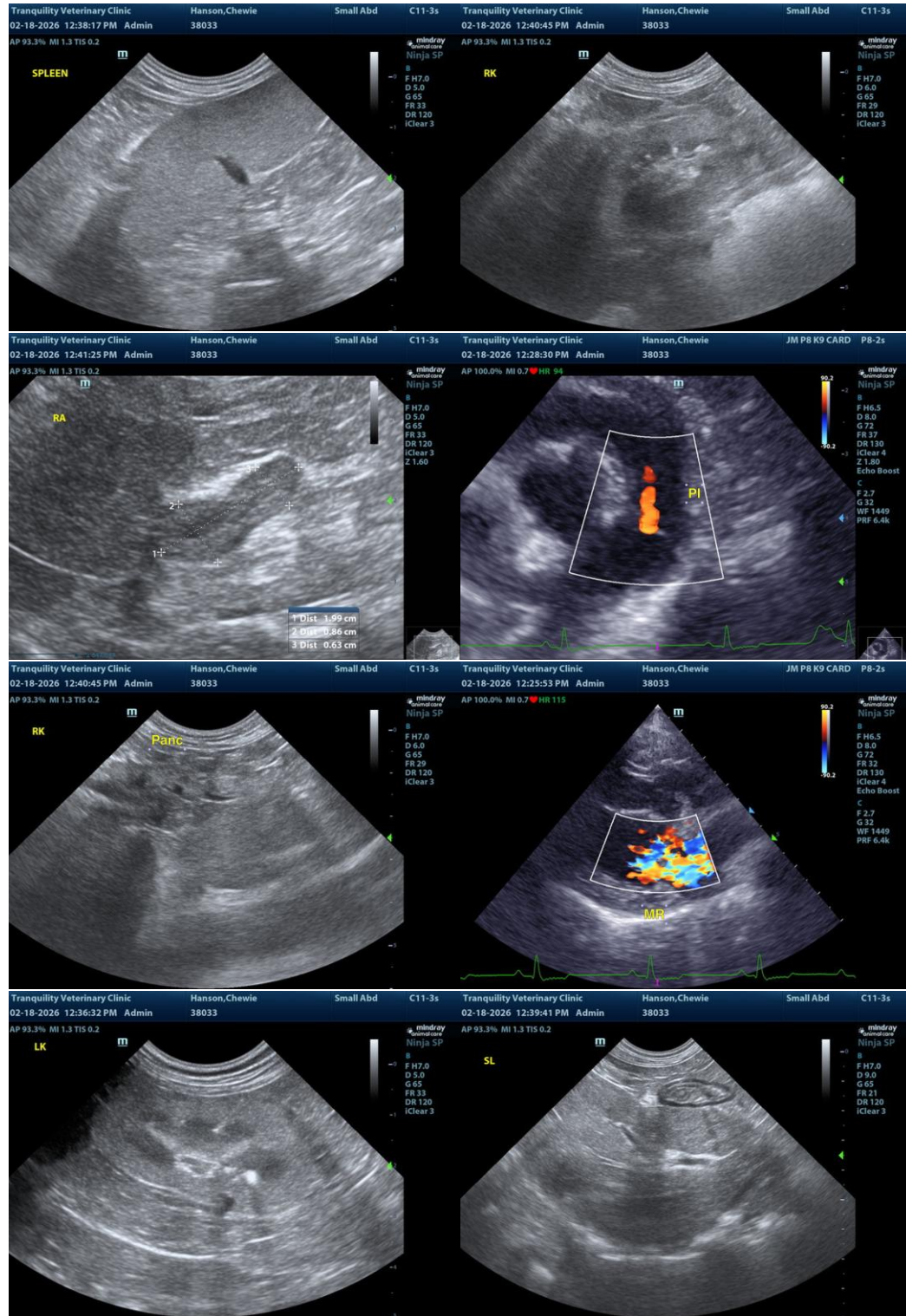
House

**INVOICE**

23930

**DATE**

02/18/2026





## PATIENT

Chewie Hanson

## SPECIES

Canine

## BREED

Dachshund

## SEX

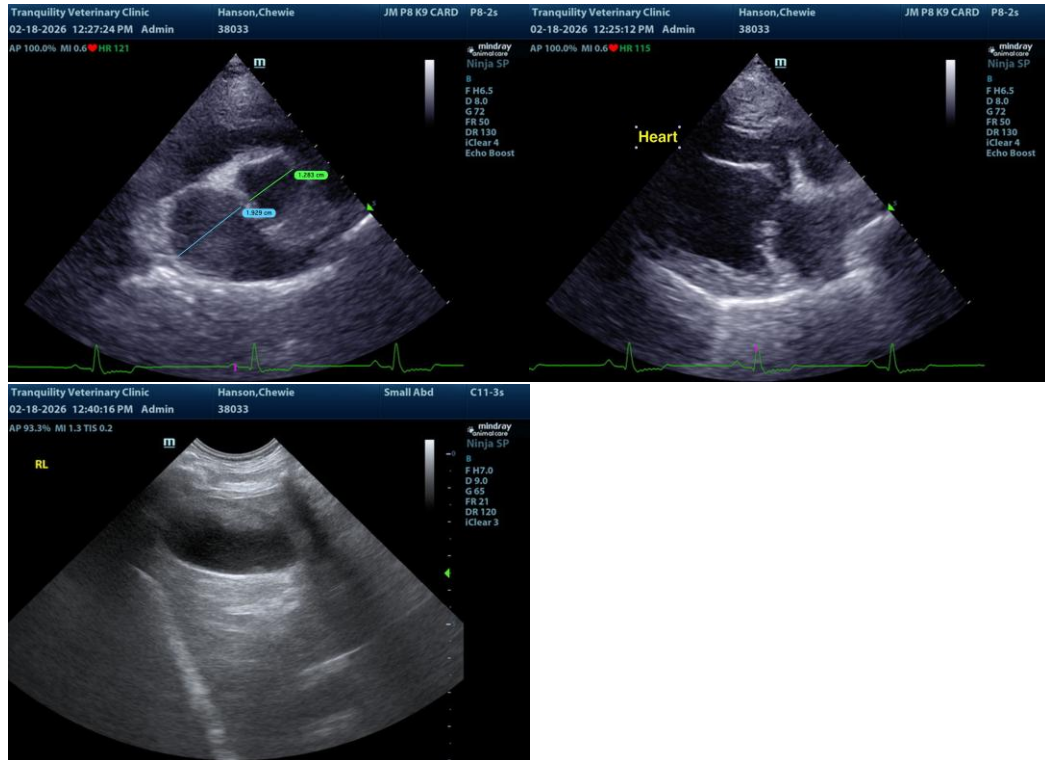
FS

## AGE

14yr

## WEIGHT

15.6



## INTERPRETED BY

R. McKenzie Daniel,  
DVM, DABVP  
(Canine and Feline)

## IMAGING PERFORMED BY

Christensen

## HOSPITAL NAME

Tranquility Veterinary  
Clinic

## REFERRING VET

House

## INVOICE

23930

## DATE

02/18/2026

The information and recommendations provided are based on the images presented by the referring veterinarian/sonographer. No evaluation can be communicated regarding pathology that was not visible in the image/video clips provided.

Thank you for this referral. If the clinical or image interpretation does not parallel your findings or if I can be of any further assistance, please contact me.

R. McKenzie Daniel, DVM, DABVP (Canine/Feline Practice)  
[info@sonopath.com](mailto:info@sonopath.com)